

Treatment of a CTO of the SFA Using the OUTBACK® Elite Re-Entry Device, SABER® .035 Balloon, and S.M.A.R.T.® Stent

By Kevin Herman, MD

PATIENT PRESENTATION

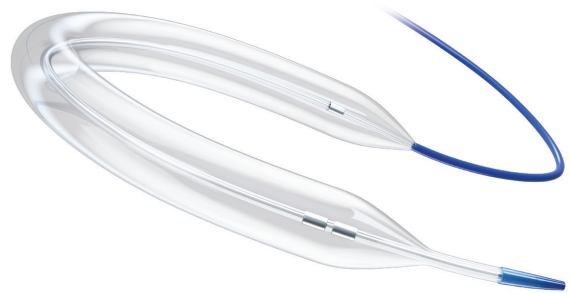A man in his early 70s with chronic limb-threatening ischemia (CLTI) presented to our institution with right foot pain and dry gangrene of the medial right heel and the right great toe (Figure 1). His past medical history included diabetes mellitus and coronary artery disease. He was on hemodialysis for end-stage renal disease.

The patient underwent a diagnostic workup of his right lower extremity, including arterial imaging. Pelvic angiography was performed using a TEMPO® UF Catheter (Cordis) (Figure 2A). Up-and-over crossing using the TEMPO® UF Catheter was performed, and angiography of the right lower extremity demonstrated a chronic total occlusion (CTO) below the superficial femoral artery (SFA) origin, distal SFA reconstitution, and diseased single-vessel runoff of the anterior tibial artery (Figure 2B-2E).

Weeks before this presentation, the patient underwent a left lower extremity intervention for CLTI, and the diagnostic angiograms obtained from that intervention were also reviewed.

PROCEDURAL OVERVIEW

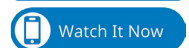Using a 6-F, 55-cm, up-and-over Raabe sheath (Cook Medical), additional angiography was performed, redemonstrating a proximal SFA occlusion; the target location for distal reentry was also identified (Figure 3A). A 0.035-inch, 180-cm Glidewire Advantage® (Terumo Interventional Systems) and a 4-F, 90-cm CXI® Support Crossing Catheter (Cook Medical) were advanced to the subintimal space after failed luminal crossing (Figure 3B). The OUTBACK® Elite Re-Entry Catheter (Cordis) was



advanced and positioned with an “L” marker oriented toward the target vessel (Figure 3C). The cannula was deployed below the intended site of reentry, and a 0.014-inch Hi-Torque Command™ Wire (Abbott) was advanced through the target vessel (Figure 3D and 3E).

Proceeding with percutaneous transluminal angioplasty (PTA), the SFA was first dilated with a 4- X 300-mm SABER® .018 PTA Balloon (Cordis) over the 0.014-inch wire (Figure 4A). The SABER® .018 Catheter was exchanged for a 6- X 200-mm SABER® .035 Balloon, which was smoothly delivered over the 0.014-inch wire (Figure 4B and 4C). After PTA, angiography revealed a spiral dissection (Figure 4D).

Next, two 6- X 150-mm S.M.A.R.T.® Vascular Stents (Cordis) and one 6- X 80-mm S.M.A.R.T.® Control Vascular Stent (Cordis) were deployed and postdilated. Imaging after stent deployment showed a patent long stent complex (Figure 5).



Sponsored by Cordis

DISCUSSION

Long-segment CTOs of the SFA can be difficult to treat. CTOs can be traversed using wire and catheter techniques, allowing for intraluminal or subintimal crossing. As detailed in this case presentation, reentry into the distal vessel was not spontaneous due to the complexity of the lesion, thus necessitating use of the OUTBACK® Elite Re-entry Catheter.

Many currently available plain old balloon angioplasty (POBA) catheters perform essentially in the same manner and ultimately yield similar clinical results. However, there are several performance characteristics that can make one balloon more favorable to an operator and should be kept in mind when choosing a “go-to” POBA catheter.

These characteristics include crossability, pushability, trackability, and tip profile. Other important factors are rewrap profile, which is described as the ability to reinsert the catheter through the sheath (once inflated), proximal and distal marker band radiopacity, and deflation times.

Although it is rare to find a POBA catheter that can perform perfectly in all specified categories, the 6- X 200-mm SABER® .035 PTA Dilatation Catheter chosen in this case performed optimally in all aforementioned categories when compared with other 0.035-inch balloon catheters. One specific area that should be highlighted is the optimal performance of the balloon in terms of the tip profile, which involves an atraumatic, tapered, smooth transition of the balloon to the guidewire.

In a case like this, with a revascularization strategy requiring long-segment subintimal crossing and use of a reentry device, the operator is usually concerned about the tip profile of the balloon catheter during traversal of the subintimal space and through the reentry point into the native vessel

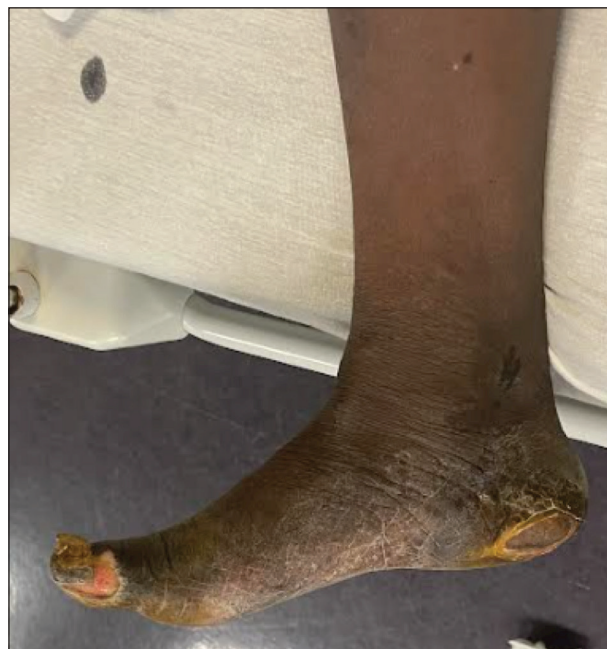

Figure 1. Image of the patient’s right foot with dry gangrene of the right heel and great toe.

lumen. Specifically, a 0.014-inch wire is needed for reentry device use. When successful luminal reentry is performed, the expected revascularization strategy generally includes wire escalation, as far as wire size goes, for delivery of specific devices. If POBA is the initial treatment option, one would typically use an 0.014- or 0.018-inch-compatible catheter to predilate after reentry. However, this limits the ability to perform a wire exchange to upsize to a 0.035-inch guidewire for delivery of 0.035-inch-compatible devices, such as a stent.

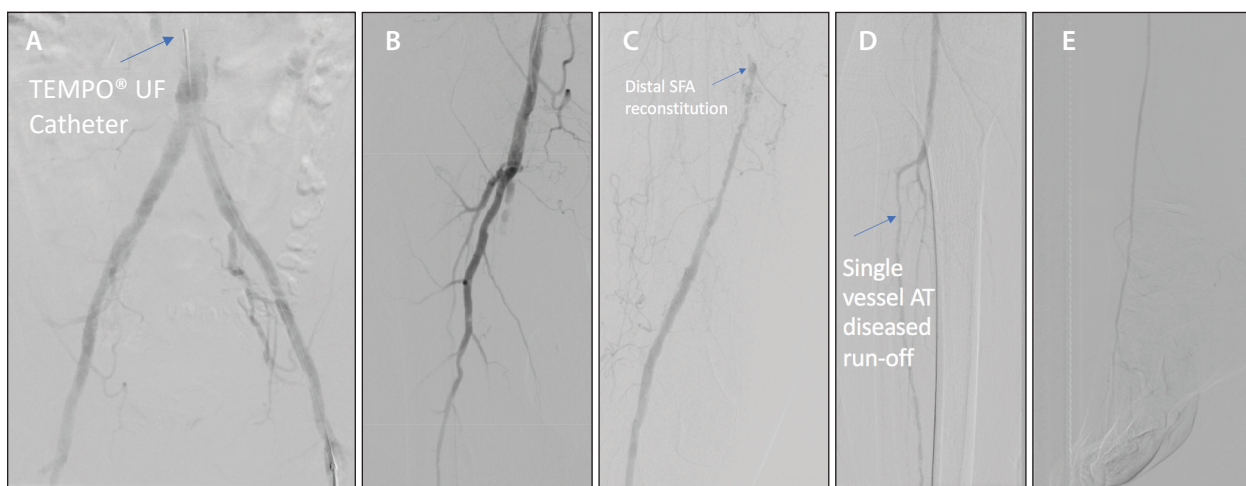


Figure 2. Diagnostic workup of the patient’s right lower extremity: pelvic angiography showing the site of proximal occlusion and distal reentry point (A); right lower extremity angiogram showing the SFA origin leading to the CTO (B), distal SFA reconstitution (C), single-vessel anterior tibial artery run-off down to the foot (D-E).

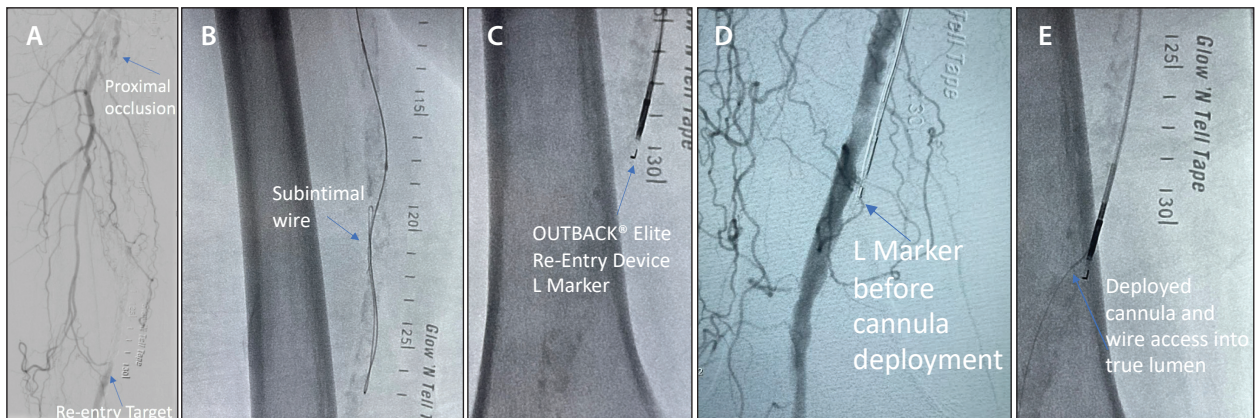


Figure 3. An angiogram of the proximal occlusion and expected distal reentry location (A). FluoroSpot image depicting the subintimal location of the Glidewire Advantage and the CXI (B). FluoroSpot image depicting the OUTBACK® Elite positioned with an “L” marker oriented toward the target vessel (C). Angiogram before cannula deployment (D) and FluoroSpot image of the deployed cannula below the original intended site of reentry and Command wire advanced through the target vessel (E).

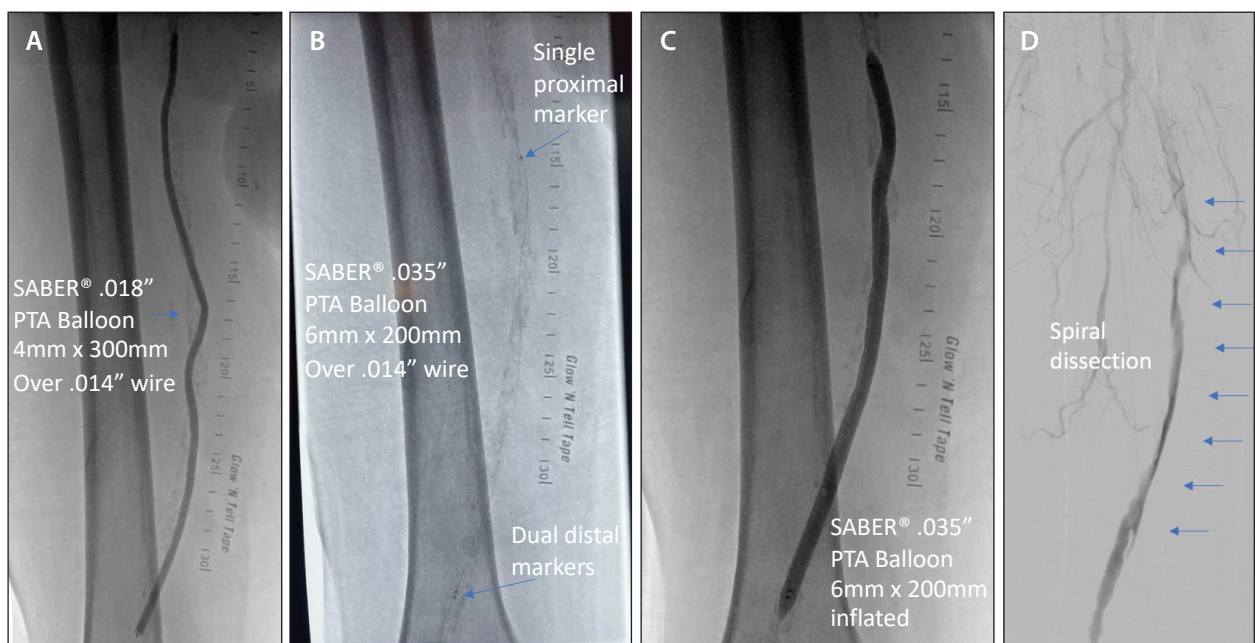


Figure 4. Initial dilatation of the SABER® .018 Balloon over a 0.014-inch wire (A), which was exchanged for the SABER® .035 Balloon (B). The SABER® .035 Balloon was delivered over the 0.014-inch wire (C) and used to dilate the SFA (D). An angiogram demonstrating the post-PTA spiral dissection.

In this case, once luminal reentry was deemed successful, we chose a 4-mm X 300-mm SABER® .018 PTA Dilatation Catheter for predilatation, which crossed easily over the 0.014-inch wire. Rather than switch out for a 0.018-inch wire, we removed the SABER® .018 Balloon Catheter and successfully crossed the lesion with the 6-mm X 200-mm SABER® .035 Balloon over the 0.014-inch guidewire. This technique allowed us to save time

and money on an extra wire exchange. The 0.035-inch SABER® Balloon tip profile and crossability were ideal for this case.

After the SABER® Balloon Catheter traversed the lesion, we exchanged for a 0.035-inch guidewire to facilitate additional devices as needed—such as the 0.035-inch-compatible S.M.A.R.T.® Stent in this case.

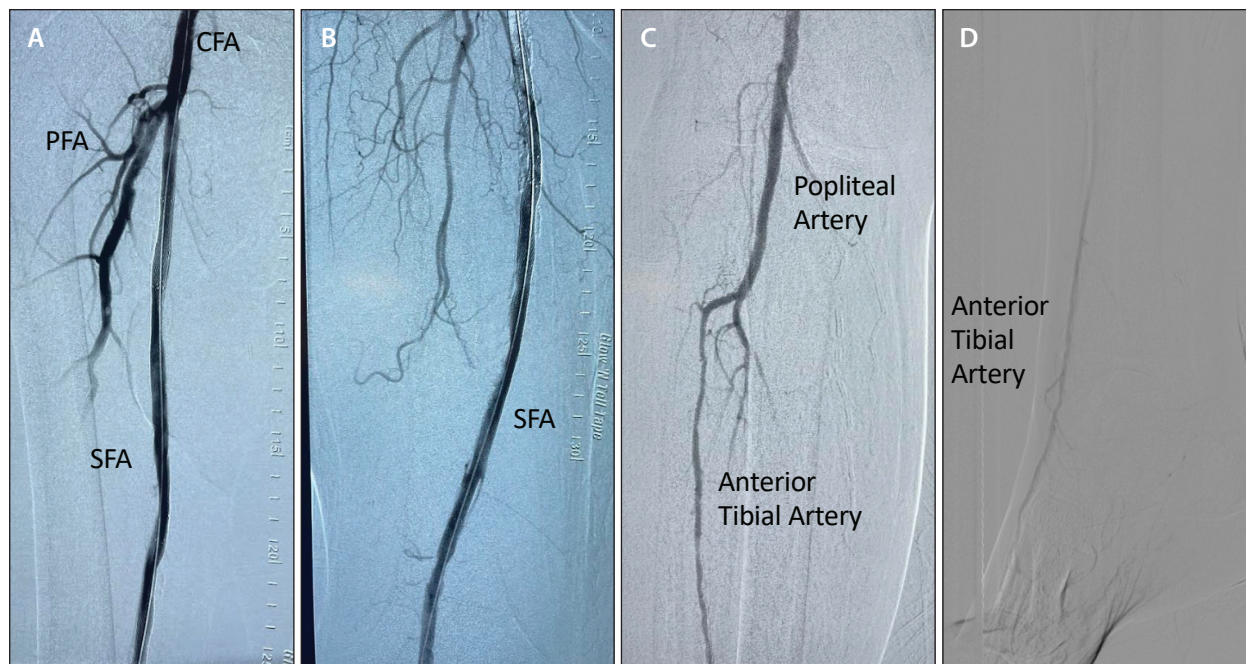


Figure 5. Angiogram after stent deployment showing the patent long stent complex.

CONCLUSION

Long-segment, calcified SFA-popliteal CTOs in diabetic patients on chronic hemodialysis with a diagnosis of CLTI often present as some of the most challenging endovascular cases. There are many endovascular tools commercially available to facilitate successful treatment in such cases. The presented case demonstrates in a step-by-step fashion a reasonable approach for treatment of a complex occlusion. Although we tend to focus on new and novel technology, this case example illustrates the use of a new and improved more basic technology.

The SABER® .035 PTA Dilatation Catheter chosen in this case performed optimally in all categories, as highlighted above, and specifically as it relates to tip profile. In

clinical follow-up of this patient, the wounds were healing, and we will evaluate if additional revascularization of the diseased tibial vessel will be needed in the future. ■

Kevin Herman, MD

Attending Physician
Interventional Institute at Holy Name Medical Center
Partner
Advanced Interventional & Vascular Services LLP
Teaneck, New Jersey
kherman@aivslip.com

Disclosures: Consultant to Cordis, CSI, and Foresight Imaging.